



PRESENTING CLINICAL SIGNS

History: Grade 3-4/6 murmur. Pre-dental evaluation.

DATE

1/9/23

ECHOCARDIOGRAPHIC FINDINGS

2D, M-mode, and Doppler study. This exam is compared to the one performed 1/24/22.

PERFORMED BY:

Kelly Vazquez

INTERPRETED BY

Keith Blass, DVM,
MS, DACVIM
(Cardiology)

There is mild left atrial dilation. The mitral valve leaflets are mildly thickened and exhibit systolic prolapse. A mild to moderate jet of eccentric mitral regurgitation is present. There is mild left ventricular dilation. Left ventricular systolic function is hyperdynamic. The aorta and aortic valve are normal. Right atrial and right ventricular dimensions are normal. The tricuspid valve appears normal, though trace tricuspid regurgitation is present. The pulmonary artery and pulmonic valve are normal. No shunting lesions are visualized. No pericardial effusion or cardiac masses are seen.

LA - 23.6 mm
LVIDd - 22.8 mm
LVIDs - 11.2 mm
FS - 50.9%
RA - 16.2 mm
LVOT - 1.20 m/s
RVOT - 1.17 m/s
TR - 2.37 m/s

PATIENT

Mr. Bean Gravis

ASSESSMENT/RECOMMENDATIONS

Degenerative mitral valve disease

SPECIES

Canine

BREED

Chihuahua

This examination demonstrates mild to moderate regurgitation of blood across Mr. Bean's mitral valve resulting from degenerative valve disease. Secondary to his regurgitation, Mr. Bean has mild dilation of both his left atrium and left ventricle, though his left ventricular systolic function is well-preserved. As only mild left heart chamber dilation is present, Mr. Bean's mitral valve disease appears to be well-compensated, and his current risk for the development of clinical signs secondary to it, such as coughing, exercise intolerance, syncope, and labored breathing, appears to be relatively low.

SEX

MN

Mr. Bean's cardiovascular risk for general anesthesia is mildly increased based on this exam, therefore, some precautions should be taken in order to minimize this risk. I recommend avoiding the use of alpha-2 agonists, ketamine, and telazol in the anesthetic protocol, as well as reducing the IV fluid rate by 25%. If possible, monitoring of heart rhythm, blood pressure, and pulse oximetry are recommended during the procedure.

AGE

7 y

I recommend starting Mr. Bean on pimobendan (1.25 mg BID), as this medication should help to slow the progression of his mitral valve disease, as well as decrease his risk for general anesthesia.

A recheck echocardiogram is recommended in 9 months to monitor for disease progression.

WEIGHT

9 lb

HOSPITAL NAME

Ringwood AH

REFERRING VET

Dr. Wilkes



DATE

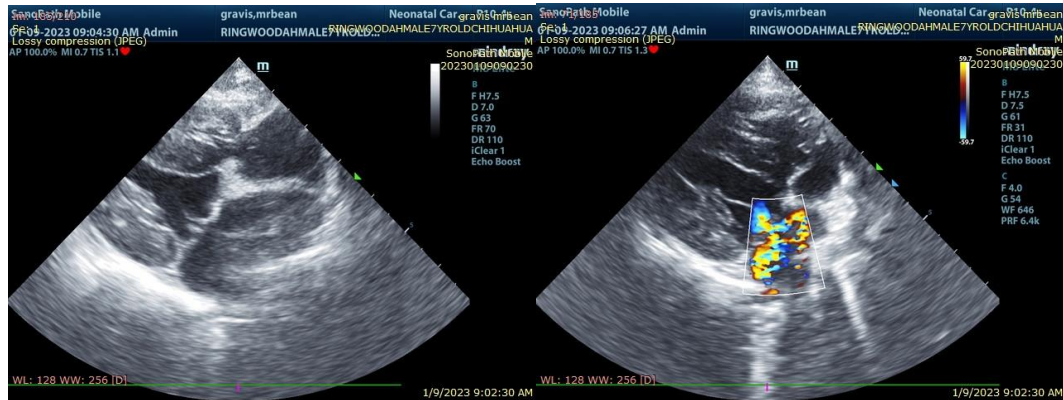
1/9/23

PERFORMED BY:

Kelly Vazquez

INTERPRETED BY

Keith Blass, DVM,
MS, DACVIM
(Cardiology)



The information and recommendations provided are based on the images presented by the referring veterinarian. No evaluation can be communicated regarding pathology that was not visible in the image/video clips provided.

PATIENT

Thank you for this referral. If the clinical or image interpretation does not parallel your findings or if I can be of any further assistance please contact me.

Mr. Bean Gravis

SPECIES

Keith Blass, DVM, MS, DACVIM (Cardiology)
KeithBlass@gmail.com
631-804-5754

Canine

BREED

Chihuahua

SEX

MN

AGE

7 y

WEIGHT

9 lb

HOSPITAL NAME

Ringwood AH

REFERRING VET

Dr. Wilkes